

SURVEY ON EFFECT OF COCAINE, SMOKING AND ALCOHOL ON DENTAL PLAQUE AND MOUTH CANCER

ZAINAB MAHMOOD ALJAMMALI

Assistant Lecturer, Department of Dentistry, College of Dentistry, Iraq

ABSTRACT

Smoking and drinking directly passes foreign material through the oral cavity, generating adverse effects on your oral cavity. Alcohol is a desiccant (drying things up); heavy drinking dramatically decreases moisture needed to maintain a healthy oral cavity. A dry mouth increases one's likelihood of developing tooth decay, gum disease, bad breath, fungal infection, burning sensations or soreness of the mouth. Alcohol's acidic nature can also erode the enamel coating on a drinker's teeth, leading to an increased chance of sensitivity and decay. Long-term contact with alcohol in the oral cavity has also been found to be possibly carcinogenic.

KEYWORDS: *Plague, Abortion*

Received: Mar 08, 2017; **Accepted:** Mar 25, 2017; **Published:** Mar 28 2017; **Paper Id.:** TJPRC: IJOMPRJUN201674

INTRODUCTION

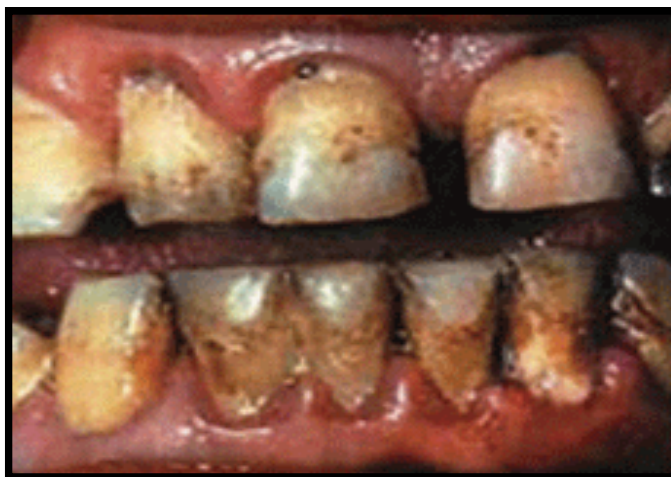Smoking is bad for the health: it increases the risk of several types of cancers (lung cancer, pancreatic cancer, cervical cancer, cancer of the kidney, liver cancer, cancers of the mouth, lip, throat, bladder cancer, stomach cancer and leukaemia), emphysema and other respiratory diseases, coronary heart disease, stroke, diabetes and ulcers. Smoking is also associated with adverse pregnancy outcomes – increased spontaneous abortions in the first trimester, premature placenta abruption, preterm delivery, decreased birth weight, sudden infant death syndrome – and earlier menopause in women and sperm abnormalities and impotence in men. It affects the senses of taste and smell.

The perils of smoking extend beyond active smokers to include those who are in their environment (i.e., passive smokers): second-hand smoke contains at least 50 known carcinogens and other harmful chemicals. Smoking is the single most important preventable cause of illness and death. It is responsible for an estimated 30% of all cancer diseases and deaths and 90% of all lung cancers. Compared to those who have never smoked, smokers are almost twice as likely to have a heart attack. Smokers shorten their life expectancy by 10–15 years on average. By simply quitting smoking, however, smokers can, over time, reduce their risk levels.

Within the EU, Ireland has the highest smoking-related annual mortality rate, with 300 people in every 100,000 or approximately 7,000 people every year dying from smoking related diseases. Some 29% of adults surveyed in SLÁN 2007 reported being current smokers, 83% of whom smoked on a daily basis. Among school age children surveyed in the HBSC 2010, 27% reported having ever smoked and 12% reported being current smokers, with older children and those from lower social classes more likely to report both behaviours.

EFFECT OF SMOOKING ON GUMS

When smoking is accompanied by alcohol consumption, its ill effects on health can be synergistically amplified: smokers who are also alcohol drinkers have a risk of oral cancer greater than the combined risk of those who only smoke and those who only drink alcohol.



Bad breath (halitosis), sinusitis and tooth discoloration will be the first signs of oral stress of a smoker, as nicotine and tar present in cigarette smoke stain the teeth. Smoking can also result in gum disease, leading to bone loss and tooth loss from decreases in blood flow and oxygen level, and increased plaque and tartar build-up. Smoking also raises the temperature of your mouth to 140-160° F, causing constant irritation and inflammation. An increased risk of developing oral cancer is also a consequence which should not to be over looked – there are 4000 different chemicals in tobacco smoke and 50 are known carcinogens.

Smoking and drinking have their own ill effects. According to a recent survey, nearly 43000 Americans would be victims to oral cancer this year. 93% of these are caused because of excessive smoking and drinking.

Smoking (Cigarettes)

There is a very famous quote that smoking is a very classy way to commit suicide. Its adverse effects is not only evident on the smoker's lungs and respiratory system but on his health as a whole. The mouth suffers the immediate consequences – gums become pale, teeth lose their white color and the taste buds and the tongue get affected. It also has a damaging effect on the mouth muscles and lead to frequent mouth and tongue dryness ultimately leading to oral cancer.

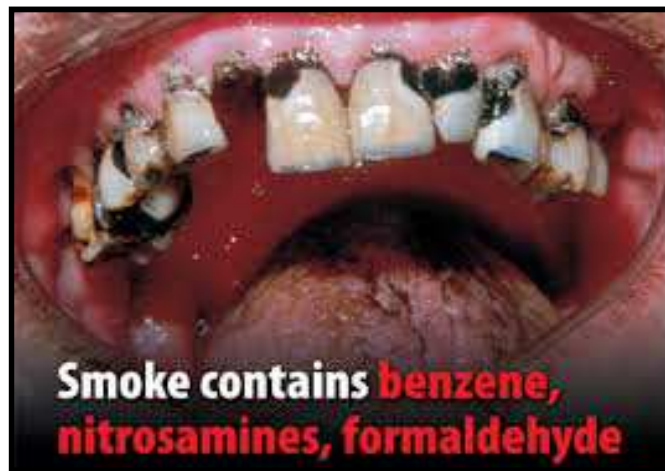
Smoking during pregnancy affects the embryo formation and very often leads to the delivery of abnormal children or physical deformities in them.

On to cigarettes... Bad breath and yellow teeth are only the superficial side effects of smoking. There are other more costly, unpleasant, and downright dangerous side effects. Because you inhale the smoke through your mouth, your mouth is nicotine central and that is also where the addictive and unhealthy things in a cigarette gain access to the rest of your body.

Periodontal disease, or gum disease, is a big problem for smokers. It can become very serious and lead to even more dangerous conditions as well. Smoking irritates gum tissue and reduces blood flow to the gums which causes damage

and can result in gums pulling away from the base of the teeth. Smoking may account for around 75% of periodontal disease in adults. If you smoke, you are at seven times greater risk than those who don't. Secondhand smoke can also put you at a higher risk of periodontal disease. One of the first and most noticeable signs is gum recession. It can expose the roots of the teeth, which leaves them vulnerable to tooth decay and infection. You may also experience some increased sensitivity in your teeth, sometimes becoming severe.

Gums will never stop deteriorating as long as one is smoking. As deterioration furthers, bacterial growth increases which leads to bad breath, cavities, mouth sores, infections and plaque growth. If plaque remains on the teeth long enough, it hardens, becomes tartar, and irritates the teeth and gums even more.



THE ROLE OF NICOTINE

The concoction of chemicals like nicotine in tobacco or smoke, and plaque bacteria leads to deterioration of the teeth. Before you realize, the teeth and the gums get considerably damaged which is irreversible. This paves the way to cavities and loosening of teeth that eventually have to be pulled out.

Alcohol

Alcohol contains good amount of sugars, which very easily settle in the mouth making it a bacteria-breeding place that feed on gums and teeth. The smoke which is drawn from a cigarette and the bacteria present together release a dangerous acid which results in stomach acidity initially and ultimately leads to oral cancer. This is also another reason to throat and intestine cancers as well. We want to make sure that you keep your whole body safe on St. Patrick's Day, but something that often gets overlooked when going out for a day and/or night of drinking alcohol is the effect that it has on your teeth. Since we are dentists, we want to make sure you don't overlook it this year!

First of all No amount of brushing will protect your teeth from harm if you do not drink in moderation. Excessive alcohol consumption can cause cavities, gum deterioration, and tooth loss. In fact, dentists can oftentimes detect early signs of alcoholism based on the state and condition of the gums and teeth.

There is a one-two punch that occurs when drinking alcohol that causes many people problems: dehydration, and sugar-packed mixed drinks.

Hard alcohol is often served with sugary mixers like sodas, juices, and energy drinks. This sugar causes tooth decay. Also, alcohol dehydrates you, and part of dehydration means that the mouth produces less saliva, which results in dry mouth. Saliva helps wash away and dissolve all the bacteria in your mouth from the sugary mixers in your drinks, so don't underestimate the significance of this.

Studies have shown that many people, particularly young people, go to bed without brushing their teeth after a night on the town. That means all that sugar remains on the teeth all night long and can really do a number, so if you're going to drink, be sure to brush your teeth afterwards before you go to bed.

Important Tip

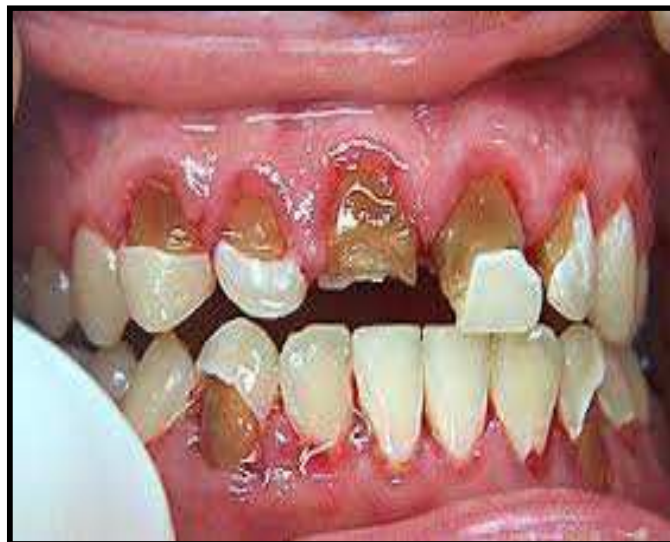Don't brush immediately after you finish your last drink because all the sugar and alcohol weakens your enamel. You should wait at least 30 minutes to let your enamel re-mineralize after being exposed to all that sugar and acid.

Drinking lots of water simultaneously while you are drinking alcohol will help to keep you from becoming intoxicated too early in the night, and it will also help wash away some of the sugars and acids that are being consumed. Similarly, the day after consuming alcohol, continue drinking lots of water to help with a rehydration and to continue protecting teeth!

Additionally, alcohol prolongs the healing process. If you are injured, or are recovering from a surgery, full recuperation will take longer for those who regularly consume alcohol as opposed to those who do not.

Cannabis

Cannabis, also known as marijuana, can cause xerostomia (dry mouth), a condition characterized by a lack of saliva production. As saliva neutralizes acids in the mouth, a lack thereof allows the acids to run rampant and erode your tooth enamel. Acid erosion causes tooth discoloration and sensitivity and makes your teeth more vulnerable to decay. Chronic dry mouth from cannabis use can cause your teeth to rot very quickly, and the chemicals in marijuana smoke increase the risk of developing oral cancer.



Cocaine

Cocaine is highly acidic, and when users rub it on their teeth and gums, tooth enamel erosion and gum irritation are inevitable. Cocaine also causes xerostomia and bruxism, a grinding and clenching of the teeth that can cause teeth to wear down. Cocaine can cause several oral health problems because of the various ways users ingest the drug. When snorted through the nose, cocaine can damage the tissue between the nostrils, which affects how you breathe and speak. When mixed with saliva, cocaine also creates a very acidic solution in the mouth that can wear away tooth enamel. Cocaine users often rub the drug on their gums which can cause ulcers or lesions in the mouth and damage the bone underneath⁴.

Ecstasy

Ecstasy, also called “E” and “the love drug,” is a form of speed. Like cocaine, it contributes to bruxism and dry mouth, both of which can lead to worn-down, decayed teeth. Ecstasy also causes nausea and vomiting, which will expose the teeth to stomach acids and present more risk of enamel erosion and decay.

Heroin

Also known as “smack,” heroin is another drug that causes dry mouth and teeth grinding. In addition, heroin users often crave sweets, which can lead to extensive tooth decay if oral hygiene is neglected during drug use.

Methamphetamine

Made from corrosive chemicals such as battery acid, paint thinner, and lye, methamphetamine is a highly acidic drug that rots teeth in a very short period of time. Crystal meth users also crave sugar, which only accelerates the rapid decay caused by the chemicals in this drug.

REFERENCES

1. United Nations Office on Drugs and Crime. *World drug report 2007*. pp 63–94. Vienna: UNODC, 2007.
2. Engel J D. Cocaine: a historical and modern perspective. *Nebr Med J* 1991; **76**: 263–270.
3. Parry J, Porter S, Scully C, Flint S, Parry M G. Mucosal lesions due to oral cocaine use. *Br Dent J* 1996; **180**: 462–464.
4. Isaacs S O, Martin P, Willoughby J H. 'Crack' (an extra potent form of cocaine) abuse: a problem of the eighties. *Oral Surg Oral Med Oral Pathol* 1987; **63**: 12–16.
5. Goldstein F J. Toxicity of cocaine. *Compend Contin Educ Dent* 1990; **11**: 710–716.
6. Lee C Y, Mohammedi H, Dixons R A. Medical and dental implications of cocaine abuse. *J Oral Maxillofac Surg* 1991; **49**: 290–293.
7. Friedlander A H, Gorelick D A. Dental management of the cocaine addict. *Oral Surg Oral Med Oral Pathol* 1988; **65**: 45–48.
8. Cone-Wesson B. Prenatal alcohol and cocaine exposure: influences on cognition, speech, language and hearing. *J Commun Disord* 2005; **38**: 279–302.
9. Morris P, Binienda Z, Gillam M P et al. The effect of chronic cocaine exposure during pregnancy on maternal and infant outcomes in the rhesus monkey. *Neurotoxicol Teratol* 1997; **18**: 147–154.
10. Al-Motabagani M A, Mohamed A S. Congenital malformations in mice induced by addiction to alcohol and cocaine. *East Afr Med J* 2005; **82**: 433–438.

11. Markov D, Jacquemyn Y, Leroy Y. Bilateral cleft lip and palate associated with increased translucency and maternal cocaine abuse at 14 weeks of gestation. *Clin Exp Obstet Gynecol* 2003; **30**: 109–110.
12. Mattson-Gates G, Jabs A D, Hugo N E. Perforation of the hard palate associated with cocaine abuse. *Ann Plast Surg* 1991; **29**: 466–468.
13. Blanksma C J, Brand H S. Cocaine abuse: orofacial manifestations and implications for dental treatment. *Int Dent J* 2005; **55**: 365–369.
14. Lancaster J, Belloso A, Wilson C A, McCormick M. A rare case of naso-oral fistula with extensive osteocartilaginous necrosis secondary to cocaine abuse: review of otorhinolaryngological presentations in cocaine addicts. *J Laryngol Otol* 2000; **114**: 630–633.
15. Mari A, Arranz C, Gimeno X et al. Nasal cocaine abuse and centrofacial destructive process: report of three cases including treatment. *Oral Surg Oral Med Oral Pathol Oral Radiol Endod* 2002; **93**: 435–439.
16. Deutsch H L, Millard D R. A new cocaine abuse complex. Involvement of nose, septum, palate, and pharynx. *Arch Otolaryngol Head Neck Surg* 1989; **115**: 235–237.
17. Villa P D. Midfacial complications of prolonged cocaine snorting. *J Can Dent Assoc* 1999; **65**: 218–223.
18. Brand H S, Blanksma C J, Gonggrijp S. A maxillary obturator for a cocaine-induced oronasal defect. *J Disabil Oral Health* 2007; **8**: 37–40.
19. Tsoukalas N, Johnson C D, Engelmeier R L, Delattre V F. The dental management of a patient with a cocaine-induced maxillofacial defect: a case report. *Spec Care Dentist* 2000; **20**: 139–142.
20. Smith J C, Kacker A, Anand V K. Midline nasal and hard palate destruction in cocaine abusers and cocaine's role in rhinologic practice. *Ear Nose Throat J* 2002; **81**: 172–177.
21. Simsek S, de Vries X H, Jol J A D et al. Sino-nasal bony and cartilaginous destruction associated with cocaine abuse, *S. aureus* and antineutrophil cytoplasmic antibodies. *Neth J Med* 2006; **64**: 248–251.
22. Kuriloff D B, Kimmelman C P. Osteocartilaginous necrosis of the sinonasal tract following cocaine abuse. *Laryngoscope* 1989; **99**: 918–924.
23. Kuriloff D B. Perforation of the hard palate associated with cocaine abuse. *Ann Plast Surg* 1992; **28**: 397.
24. Sousa O, Rowley S. Manifestaciones otorinolaringológicas por el abuso intranasal de cocaína. A proposito de un caso. *Rev Med Panama* 1994; **19**: 55–60.
25. Armstrong M, Shikani A H. Nasal septal necrosis mimicking Wegner's granulomatosis in a cocaine abuser. *Ear Nose Throat J* 1996; **75**: 623–626.
26. Helie F, Fournier J. Destructive lesions of the median line secondary to cocaine abuse. *J Otolaryngol* 1997; **26**: 67–69.
27. Sastry R C, Lee D, Har-El G. Palate perforation from cocaine abuse. *Otolaryngol Head Neck Surg* 1997; **116**: 565–566.
28. Gendeh B S, Ferguson B J, Johnson J T, Kapadia S. Progressive septal and palatal perforation secondary to intranasal cocaine abuse. *Med J Malaysia* 1998; **53**: 435–438.
29. Sittel C, Eckel H E. Nasal cocaine abuse presenting as a central destructive granuloma. *Eur Arch Otorhinolaryngol* 1998; **255**: 446–447.

30. Braverman I, Raviv E, Frienkiel S. Severe avascular necrosis of the nasal chambers secondary to cocaine abuse. *J Otolaryngol* 1999; **28**: 351–353.